SVOA Dentistry

e-ISSN 2753-9172

ScienceVolks Open Access

Case Report

Immediate Full-Arch Implant Rehabilitation, Palatal Rotational Flap Closure of a Chronic Oroantral Fistula, and Autologous Facial Lipofilling in a 60-Gy Post-Radiotherapy Patient: A Multidisciplinary Surgical Approach

Ahmed Hisham Moustafa Mohamed Elzun*

Maxillofacial Center, Alexandria, Egypt.

***Corresponding Author**: Ahmed Hisham Moustafa Mohamed Elzun, Maxillofacial Center, Alexandria, Egypt.

https://doi.org/10.58624/SVOADE.2026.07.042

Received: September 16, 2026

Published: November 28, 2026

Citation: Mohamed Elzun AHM. Immediate Full-Arch Implant Rehabilitation, Palatal Rotational Flap Closure of a Chronic Oroantral Fistula, and Autologous Facial Lipofilling in a 60-Gy Post-Radiotherapy Patient: A Multidisciplinary Surgical Approach. *SVOA Dentistry* 2026, 7:6, 335-338. doi: 10.58624/SVOADE.2026.07.042

Abstract

Background: Head and neck radiotherapy can result in long-term tissue changes that complicate oral surgical procedures, dental implant rehabilitation, and wound healing. Management becomes particularly challenging when a chronic oroantral fistula persists despite previous surgical closure attempts.

Case Description: A 50-year-old male patient with a history of nasopharyngeal carcinoma treated with 60 Gy radiotherapy 20 years previously presented with a chronic right oroantral fistula that developed following extraction of the right upper third molar and had persisted for 7 years. A previous attempt at closure using a buccal advancement flap had failed, with the fistula remaining for approximately 3 years. Comprehensive rehabilitation was performed through complete clearance of the remaining roots followed by immediate full-arch implant rehabilitation. The chronic oroantral fistula was closed using a palatal rotational flap. Autologous facial lipofilling using abdominal fat was performed during the same treatment, with platelet-rich plasma also administered. Postoperatively, pentoxifylline therapy was continued for 3 months. The patient was clinically followed for 3 months, and definitive prosthetic rehabilitation was completed 2 months after surgery.

Conclusions: This case demonstrates a multidisciplinary approach to complex oral and facial rehabilitation in a previously irradiated patient with a long-standing oroantral fistula and previous failed closure. The combination of immediate full-arch implant rehabilitation, palatal rotational flap closure, autologous facial lipofilling, platelet-rich plasma, and postoperative supportive therapy resulted in successful clinical rehabilitation during the reported follow-up period.

Keywords: *Oroantral fistula; Radiotherapy; Dental implants; Full-arch rehabilitation; Palatal rotational flap; Autologous fat grafting*

Introduction

Radiotherapy for head and neck malignancies can produce long-term changes in the oral and maxillofacial tissues, including vascular and soft-tissue alterations that may compromise healing and increase the risk of complications following oral surgery. Dental implant rehabilitation in irradiated patients therefore requires careful treatment planning and consideration of radiation-related risks. [1,2]

Oroantral fistula is an abnormal epithelialized communication between the oral cavity and maxillary sinus, most commonly associated with extraction of posterior maxillary teeth.

Chronic fistulae may become particularly challenging when they have been present for a prolonged period or when previous closure attempts have failed. Several local flap techniques have been described, including buccal advancement, buccal fat pad, and palatal rotational flaps. [3,4]

Palatal rotational flaps provide a well-vascularized, relatively thick tissue flap and have been described as particularly useful for delayed closure of large or chronic oroantral fistulae, including cases in which previous buccal flap closure has failed. [5]

Autologous fat grafting has also been used in patients who have undergone treatment for head and neck malignancies to improve facial soft-tissue volume and aesthetic contour, including in previously irradiated tissues.

The present case describes the comprehensive surgical rehabilitation of a previously irradiated patient with a chronic oroantral fistula and failed previous closure, combining immediate full-arch implant rehabilitation, palatal rotational flap closure, and autologous facial lipofilling. [6]

Case Presentation

A 50-year-old male patient with a medical history of nasopharyngeal carcinoma presented for comprehensive oral and facial rehabilitation.

The patient had received radiotherapy for nasopharyngeal carcinoma approximately 20 years previously, with a reported total radiation dose of 60 Gy.

Approximately 7 years before the current treatment, the patient underwent extraction of the right upper third molar. Following the extraction, a large right oroantral fistula developed and persisted chronically.

A previous surgical attempt to close the fistula using a buccal advancement flap had been performed approximately 3 years before the current treatment. The closure was unsuccessful, and the oroantral fistula persisted.

Because of the extensive dental condition and the chronic oroantral communication, a comprehensive surgical rehabilitation plan was established.

The remaining dental roots were completely cleared, followed by immediate full-arch implant rehabilitation.

The chronic oroantral fistula was surgically excised and closed using a palatal rotational flap, providing vascularized soft-tissue coverage of the defect.

In the same treatment, autologous facial lipofilling was performed using abdominal fat to restore facial soft-tissue volume and improve facial contour. Platelet-rich plasma (PRP) was also administered as an adjunctive procedure.

Considering the patient's previous exposure to 60 Gy radiotherapy and the potential risk of impaired tissue healing and osteoradionecrosis, postoperative pentoxifylline therapy was continued for 3 months.

The patient was clinically followed for 3 months after surgery. Healing of the surgical sites was satisfactory during the follow-up period. Definitive prosthetic rehabilitation was completed 2 months after surgery.



Figure 1

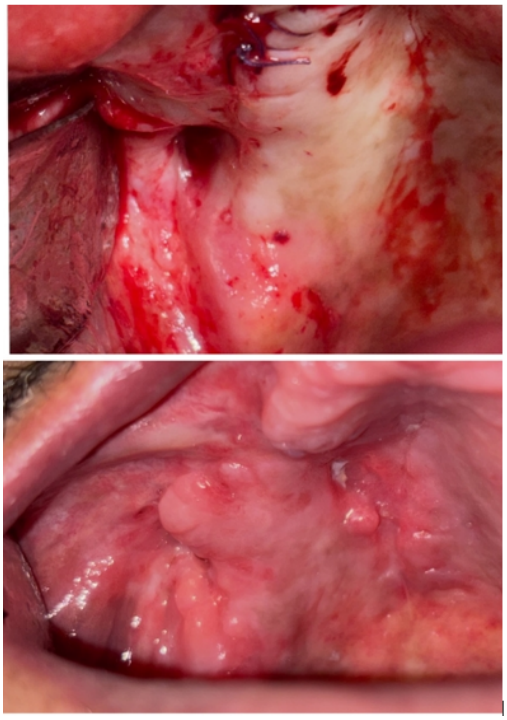

Figure 2

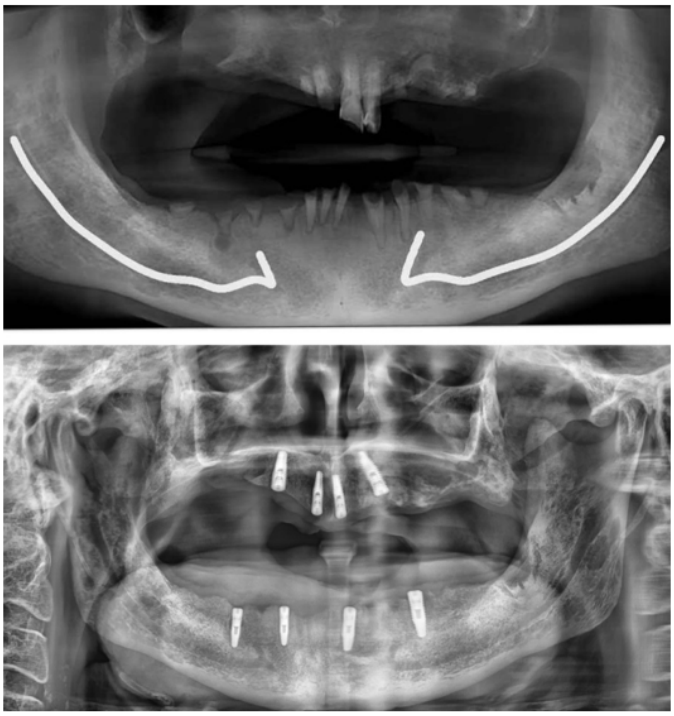

Figure 3

Discussion

The management of oral rehabilitation in patients previously treated with head and neck radiotherapy presents significant clinical challenges. Radiation-associated tissue changes may negatively influence vascularity, healing capacity, and the biological response to surgical trauma. Implant placement in irradiated patients remains feasible, but systematic reviews have demonstrated that implant survival may be lower than in non-irradiated sites and that careful patient selection and postoperative monitoring are important.

In the present case, the patient had received 60 Gy approximately two decades before the surgical intervention. The prolonged interval since radiotherapy did not eliminate the relevance of his previous radiation exposure, particularly in the context of extensive oral surgery and implant rehabilitation.

The chronic oroantral fistula represented an additional major surgical challenge. The fistula had persisted for 7 years and had previously failed to respond to a buccal advancement flap. Previous clinical experience has demonstrated that palatal rotation-advancement flaps can be effective for delayed closure of oroantral fistulae and may be particularly useful after unsuccessful buccal flap closure. Their advantages include substantial tissue thickness and reliable vascularity through the greater palatine vascular supply.

The choice of a palatal rotational flap in this case therefore provided a vascularized local tissue option for closure of a long-standing fistula while avoiding further reduction of the buccal vestibular depth.

Another important aspect of the treatment was the simultaneous use of immediate full-arch implant rehabilitation. Implant rehabilitation after radiotherapy requires consideration of radiation dose, anatomical site, timing, and individual patient factors. Previous systematic reviews have demonstrated that although implant rehabilitation can be successful in irradiated patients, radiation exposure remains an important risk factor for implant complications and failure.

The facial component of the rehabilitation was addressed through autologous abdominal fat grafting. Autologous fat grafting has been reported as a useful reconstructive and aesthetic technique in patients undergoing head and neck cancer rehabilitation, including patients previously exposed to radiotherapy.

The additional use of PRP and postoperative pentoxifylline therapy formed part of the supportive strategy in this high-risk surgical setting. Pentoxifylline-containing protocols have been investigated in relation to radiation-associated tissue injury and osteoradionecrosis, although the available evidence remains heterogeneous and does not establish a universal protocol for every irradiated patient.

The combination of procedures allowed the patient to undergo functional dental rehabilitation and simultaneous facial soft-tissue correction within a multidisciplinary surgical plan.

Conclusion

This case illustrates the complexity of comprehensive oral and facial rehabilitation in a patient with a remote history of 60-Gy radiotherapy, a 7-year chronic oroantral fistula, and a previously failed buccal advancement flap.

The combination of immediate full-arch implant rehabilitation, palatal rotational flap closure, autologous abdominal fat facial lipofilling, PRP, and postoperative pentoxifylline therapy provided a comprehensive approach to functional and aesthetic rehabilitation.

The satisfactory clinical course during the 3-month follow-up highlights the potential role of carefully planned multidisciplinary management in selected previously irradiated patients with complex oral surgical problems.

Conflict of Interest

The author declares no conflict of interest.

Acknowledgement

None.

References

1. Kwon MS, Lee BS, Choi BJ, Lee JW, et al. Closure of oroantral fistula: a review of local flap techniques. *J Korean Assoc Oral Maxillofac Surg.* 2020;46(1):58-65. doi:10.5125/jkaoms.2020.46.1.58.

2. Anavi Y, Gal G, Silfen R, Calderon S. Palatal rotation-advancement flap for delayed repair of oroantral fistula: a retrospective evaluation of 63 cases. *Oral Surg Oral Med Oral Pathol Oral Radiol Endod.* 2003;96(5):527-534. doi:10.1016/S1079-2104(03)00470-0.

3. Toneatti DJ, Graf RR, Burkhard JP, Schaller B. Survival of dental implants and occurrence of osteoradionecrosis in irradiated head and neck cancer patients: a systematic review and meta-analysis. *Clin Oral Investig.* 2021;25(10):5579-5593. doi:10.1007/s00784-021-04065-6.

4. Chambrone L, Mandia J Jr, Shibli JA, Romito GA, Abrahao M. Dental implants installed in irradiated jaws: a systematic review. *J Dent Res.* 2013;92(12 Suppl):119S-130S. doi:10.1177/0022034513504947.

5. Kolokythas A, et al. Management of osteoradionecrosis of the jaws with pentoxifylline-tocopherol: a systematic review of the literature and meta-analysis. *Int J Oral Maxillofac Surg.* 2019;48(2):173-180.

6. Gormley J, Copeland AE, Augustine H, McRae M. Autologous craniofacial fat grafting in the irradiated field. *J Craniofac Surg.* 2021. doi:10.1097/SCS.0000000000007549.

Copyright: © 2026 All rights reserved by Mohamed Elzun AHM. This is an open access article distributed under the Creative Commons Attribution License, which permits unrestricted use, distribution, and reproduction in any medium, provided the original work is properly cited.