SVOA Orthopaedics

e-ISSN 2752-9576

ScienceVolks Open Access

Case Report

Marginal Excision of a Large Intramuscular Hibernoma of the Right Proximal Thigh Causing Femoral Nerve Compression: A Case Report

Oussama Chaar, MD[1*], Youssef Shams, MSc[1], Remi Chaar, MD[2], Alameldine Hamed, MD[1], Hazem Hassouna, MD[1]

[1]Department of Orthopedic Surgery, Advanced Hip & Knee Surgery Center, Burjeel Hospital, Abu Dhabi, United Arab Emirates.

[2]Clinique Universitaire Saint-Luc, Brussels, Belgium.

***Corresponding Author:** Dr. Oussama Chaar, Consultant Orthopedic Surgeon, Advanced Hip & Knee Surgery Center, Burjeel Hospital, Abu Dhabi, United Arab Emirates.

https://doi.org/10.58624/SVOAOR.2026.06.036

Received: October 28, 2026

Published: November 24, 2026

Citation: Chaar O, Shams Y, Chaar R, Hamed A, Hassouna H. Marginal Excision of a Large Intramuscular Hibernoma of the Right Proximal Thigh Causing Femoral Nerve Compression: A Case Report. *SVOA Orthopaedics 2026*, 6:6, 273-278. doi: 10.58624/SVOAOR.2026.06.036

Abstract

Background: Hibernoma is a rare benign tumor of brown adipose tissue with a predilection for the thigh. Large, deep lesions may compress adjacent neurovascular structures and can mimic atypical lipomatous tumor/well-differentiated liposarcoma (ALT/WDLS) on imaging.

Case presentation: A 34-year-old man presented with a progressively enlarging mass of the right proximal anterior thigh of more than 18 months' duration, with anterior thigh numbness and quadriceps weakness consistent with femoral nerve compression. Contrast-enhanced magnetic resonance imaging (MRI) showed a well-defined, predominantly fatty, mildly enhancing intramuscular mass (9.8 × 8.3 × 13.7 cm) centered within the iliopsoas and pectineus muscles and displacing the femoral neurovascular bundle; the radiological impression was atypical lipomatous neoplasm. Open biopsy demonstrated hibernoma with negative MDM2 immunohistochemistry. The patient underwent elective excision under general anesthesia, including excision of the biopsy tract, proximal-to-distal protection of the femoral neurovascular bundle, and ligation of feeding vessels including a proximal pedicle near the lesser trochanter. Estimated blood loss was 200 mL, with no intraoperative complications. Histopathology confirmed hibernoma (14 × 11.5 × 5 cm) without atypia; the lesion reached the inked surface over approximately 30% of its circumference.

Conclusion: Large intramuscular hibernomas in the region of the femoral triangle can cause femoral neuropathy and radiologically mimic ALT/WDLS. Preoperative biopsy with MDM2 assessment, followed by marginal excision with meticulous neurovascular protection, allows safe removal with modest blood loss.

Keywords: *Hibernoma; brown fat tumor; femoral nerve compression; atypical lipomatous tumor; thigh mass; case report*

Introduction

Hibernoma is an uncommon benign adipocytic neoplasm showing brown-fat differentiation [1,2]. It accounts for approximately 1% of all adipocytic tumors and less than 2% of benign lipomatous neoplasms [3]. The lesion was first described by Merkel in 1906 as a "pseudolipoma" and was named hibernoma by Gery in 1914 because of its resemblance to the brown fat of hibernating animals [4]. It occurs most often in adults, and the thigh is the most frequent site, followed by the shoulder, back, and neck [2].

Hibernomas typically present as slow-growing, painless masses [2]. When large or deep-seated they may compress adjacent nerves; femoral nerve compression with motor and sensory deficits has been reported only rarely [3–5], and obturator nerve compression has also been described [6]. Because hibernomas may overlap clinically, radiologically, and histologically with ALT/WDLS, assessment of MDM2 by immunohistochemistry or, preferably, fluorescence in situ hybridization (FISH) is valuable in excluding malignancy [1,7].

Complete excision is the treatment of choice for symptomatic lesions and is associated with a very low risk of recurrence [2]. We report a large intramuscular hibernoma centered within the iliopsoas and pectineus muscles that produced progressive femoral neuropathy and was radiologically suggestive of an atypical lipomatous neoplasm, and we describe the surgical strategy used to protect the femoral neurovascular bundle. This report was prepared in accordance with the CARE guidelines [8].

Case Presentation

Patient information and clinical findings

A 34-year-old man presented with a progressively enlarging soft-tissue mass of the right proximal anterior thigh that had been present for more than 18 months. Over time he developed numbness of the anterior thigh and weakness, and examination demonstrated objectively reduced quadriceps strength attributable to femoral nerve compression. There were no systemic symptoms.

Diagnostic assessment

Contrast-enhanced MRI of the right thigh (8 August 2026) demonstrated a large, well-defined intramuscular mass centered within the right iliopsoas and pectineus muscles, measuring approximately 9.8 × 8.3 × 13.7 cm (anteroposterior × transverse × craniocaudal). The lesion was predominantly hyperintense on T1- and T2-weighted images, with signal suppression on fat-saturated sequences indicating a predominantly fatty composition, and showed mild internal enhancement after contrast administration. No necrosis or fluid–fluid levels were identified. The mass displaced the adjacent musculature and the femoral neurovascular structures, without osseous invasion or marrow signal abnormality in the femur. Thinning/atrophy of the adductor muscle group was noted, and no pathologically enlarged regional lymph nodes were seen. The radiological impression was an atypical lipomatous neoplasm, and histopathological correlation was recommended (Figure 1).

An open biopsy of the mass was performed. Histopathology (report verified 4 September 2026) demonstrated an adipocytic neoplasm composed of mature adipocytes admixed with multivacuolated cells containing granular eosinophilic cytoplasm. Nuclei were bland, without significant pleomorphism, atypical mitoses, or necrosis. Immunohistochemical staining for MDM2 was negative. The findings were interpreted as hibernoma; given the large size, intramuscular location, and radiological suspicion of an atypical lipomatous neoplasm, complete excision was recommended for definitive evaluation.

Preoperative ultrasound was used to map the femoral artery proximal and distal to the tumor. At the level of the mass the artery could not be visualized because of deep displacement and compression. Skin markings were placed to facilitate intraoperative identification of the neurovascular structures.

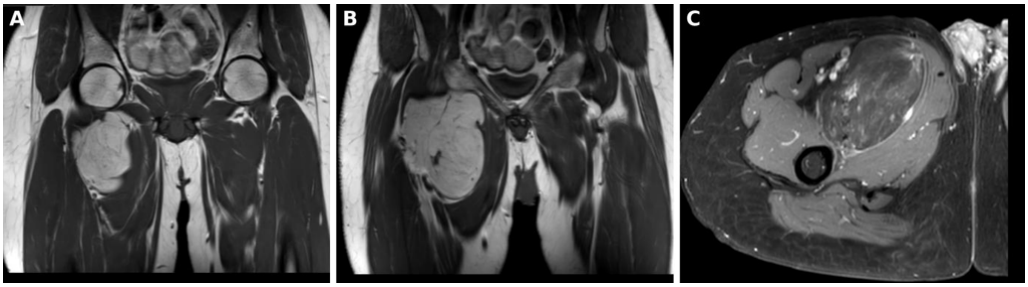

Figure 1. Preoperative MRI. (A, B) Coronal T1-weighted images showing a large, well-circumscribed, lobulated mass with signal intensity similar to subcutaneous fat and thin internal septa in the right proximal medial thigh, inferomedial to the femoral head. (C) Axial contrast-enhanced fat-suppressed T1-weighted image showing signal suppression of the lesion with heterogeneous mild internal enhancement and displacement of the adjacent femoral vessels.

Therapeutic intervention

On 13 October 2026 the patient underwent elective excision under general anesthesia. The previous biopsy incision was excised and extended to provide adequate exposure (Figure 2). The femoral neurovascular bundle was first identified proximal to the tumor and then carefully dissected distally. The femoral vessels, saphenous vein, and adjacent nerve branches were protected throughout (Figure 3). Blunt dissection was performed around the mass; although no dense adhesions were encountered, a cuff of adjacent muscle fibers was included with the specimen as a precautionary margin.

Because of the characteristically rich vascularity of hibernoma, multiple feeding vessels were ligated. The tumor extended proximally toward the lesser trochanter, anterior to the hip joint, where its principal vascular pedicle was identified and controlled. Macroscopically complete removal was achieved. The surgical field was irrigated with pulsed lavage, hemostasis was confirmed, and no residual tumor was visible. An absorbable gelatin sponge (Gelfoam) was applied within the cavity, and the wound was closed layer by layer to obliterate dead space; no drain was used. Estimated blood loss was approximately 200 mL. No intraoperative complications occurred, and the patient was transferred to the recovery unit in stable condition.

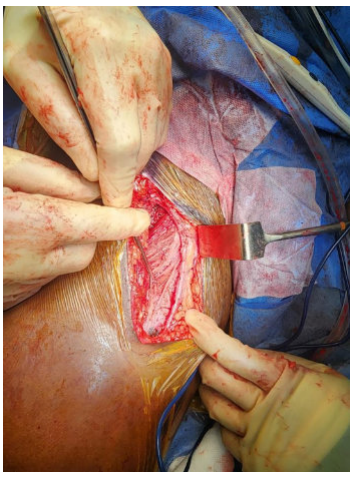

Figure 2. Intraoperative view of the right proximal thigh showing the extended incision and retraction for exposure of the deep surgical field.

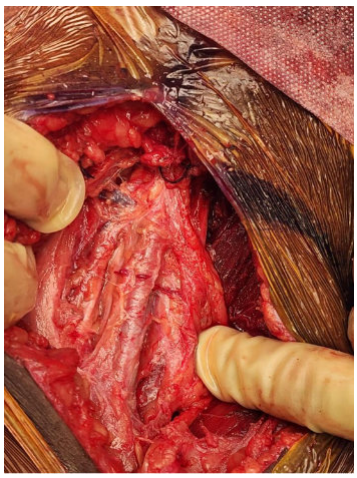

Figure 3. Tumor bed after excision of the mass, showing the dissected and preserved femoral neurovascular structures, with ligatures on feeding vessels proximally.

Pathology

The resected specimen consisted of a nodular, focally encapsulated yellow mass measuring 14 × 11.5 × 5 cm. The external surface showed focal grayish-brown areas and a 3.5 × 2 cm focus of skeletal muscle. A suture marked the prior biopsy site. The cut surface was pale yellow with a small grayish-brown focus and a grayish-white chalky area near the capsule; the remainder was homogeneous (Figure 4).

Microscopic examination revealed sheets of large polygonal brown-fat cells with finely vacuolated, voluminous cytoplasm and normochromatic round nuclei with small nucleoli, admixed with univacuolated white-fat cells. Foci of myxoid change, fibrosis, and congested vessels were present. Inflammation related to the prior biopsy (foamy and hemosiderin-laden macrophages, lymphocytes, plasma cells, eosinophils, and foreign-body giant cells) was noted. The lesion reached the inked surface over approximately 30% of the examined circumference; elsewhere it was bounded by a fibrous capsule-like rim 0.1–0.6 mm thick with adjacent fibroadipose tissue and skeletal muscle. No nuclear pleomorphism, mitotic activity, or features of malignancy were identified, and MDM2 immunohistochemistry was negative. The diagnosis of hibernoma was confirmed.



Figure 4. Gross specimen of the excised hibernoma (14 × 11.5 × 5 cm) in a kidney basin, showing the lobulated, encapsulated mass with prominent surface vasculature and marking sutures.

Follow-up and outcomes

The immediate postoperative course was uneventful. Clinical surveillance is ongoing to assess wound healing, recovery of anterior thigh sensation and quadriceps strength, and local recurrence.

Timeline

Table 1. Timeline of clinical events.

Time point	Event
>18 months before presentation	Onset of a slowly enlarging mass of the right proximal anterior thigh
Before presentation	Progressive anterior thigh numbness and quadriceps weakness
8 August 2026	Contrast-enhanced MRI: 9.8 × 8.3 × 13.7 cm predominantly fatty intramuscular mass within the iliopsoas and pectineus; radiological impression of atypical lipomatous neoplasm
Report verified 4 September 2026	Open biopsy: hibernoma; MDM2 immunohistochemistry negative
Preoperative	Ultrasound mapping of the femoral artery with skin marking
13 October 2026	Marginal excision under general anesthesia; estimated blood loss 200 mL; no intraoperative complications
Postoperative	Uneventful recovery; final histopathology confirmed hibernoma (14 × 11.5 × 5 cm); clinical surveillance ongoing

Discussion

This case illustrates several clinically relevant features of large, deep hibernomas. First, the anatomical location explains the neurological presentation. The mass was centered within the iliopsoas and pectineus, which form the floor of the femoral triangle on which the femoral nerve and vessels lie; expansion of a large intramuscular tumor at this level displaced the femoral neurovascular bundle and produced progressive femoral neuropathy. Comparable cases are few. Huang et al. described an 11 × 9 × 4 cm hibernoma of the anterolateral proximal thigh causing femoral mononeuropathy in a 26-year-old man; after marginal excision, sensation and muscle strength had recovered to near-normal levels at 4 months [4]. Beidas et al. reported an approximately 13 cm medial thigh hibernoma adjacent to the femoral artery in which the course of the femoral nerve was altered by mass effect [5], and Galustov et al. described a 20 cm anteromedial proximal thigh hibernoma compressing the femoral nerve, without recurrence at 6 months [3]. The adductor atrophy seen on MRI in our patient raises the possibility of additional pressure on the adductor compartment or the obturator nerve, which has also been reported with thigh hibernomas [6]; this was not formally assessed.

Second, the imaging appearance of hibernoma can closely mimic ALT/WDLS. In our patient the radiological impression was an atypical lipomatous neoplasm. In a series of 64 hibernomas histologically mimicking ALT, most tumors were deep-seated, the median size was 12.9 cm, and two-thirds arose in the thigh—a profile closely matching the present case [7]. Preoperative biopsy was therefore essential. Negative MDM2 immunohistochemistry supported hibernoma, and the final histology—multivacuolated brown-fat cells with bland nuclei, admixed univacuolated adipocytes, and no atypia—fulfilled WHO diagnostic criteria [1]. MDM2 FISH, the reference method for detecting MDM2 amplification, was not performed.

Third, hibernomas are hypervascular, as reflected by the internal enhancement on MRI and the multiple feeding vessels encountered at surgery. Preoperative ultrasound mapping of the femoral artery, early proximal identification of the neurovascular bundle with proximal-to-distal dissection, and controlled ligation of feeding vessels—particularly the principal pedicle near the lesser trochanter—limited blood loss to 200 mL. The biopsy tract was excised with the specimen in keeping with oncological principles, and the cavity was managed with a hemostatic gelatin sponge and layered closure without a drain.

Complete excision is considered curative. In the largest clinicopathological series, none of 66 patients followed for a mean of 7.7 years developed recurrence or metastasis, including eight with intramuscular tumors [2], and no recurrences were observed among the 16 hibernomas mimicking ALT with available follow-up [7]. In the present case excision was macroscopically complete, but the lesion reached the inked surface over approximately 30% of its circumference, consistent with a marginal excision. Given the benign behavior of hibernoma, clinical surveillance rather than re-excision was chosen.

The principal limitation of this report is the short postoperative follow-up, which does not yet allow assessment of neurological recovery or recurrence. In addition, a numerical muscle-strength grade was not available, and MDM2 amplification was not assessed by FISH.

Conclusion

A large intramuscular hibernoma centered within the iliopsoas and pectineus can cause progressive femoral nerve compression and may be radiologically indistinguishable from ALT/WDLS. Preoperative biopsy with MDM2 assessment is key to the diagnosis. Marginal excision with early identification and continuous protection of the femoral neurovascular bundle and controlled ligation of feeding vessels is feasible with modest blood loss and is expected to be curative.

Declarations

Consent for publication: Written informed consent was obtained from the patient for publication of this case report and accompanying images.

Competing interests: The authors declare that they have no competing interests.

Funding: None.

Author contributions: OC was the primary operating surgeon and YS was the assisting surgeon. Both authors contributed to data collection, literature review, and the drafting and critical revision of the manuscript, and both read and approved the final version.

Availability of data and materials: Not applicable.

References

1. WHO Classification of Tumours Editorial Board. Soft tissue and bone tumours. 5th ed. Lyon: International Agency for Research on Cancer; 2020.

2. Furlong MA, Fanburg-Smith JC, Miettinen M. The morphologic spectrum of hibernoma: a clinicopathologic study of 170 cases. Am J Surg Pathol. 2001;25(6):809-14. doi:10.1097/00000478-200106000-00014

3. Galustov AM, Sofronov DI, Kozlov NA, Fedorova AV, Batyrova GS, Borzov KA. Hibernoma: a case report and discussion of a rare tumor. Sarkomy kostei, myagkikh tkanei i opukholi kozhi (Bone and Soft Tissue Sarcomas, Tumors of the Skin). 2023;15(2):46-52. Russian.

4. Huang C, Zhang L, Hu X, Liu Q, Qu W, Li R. Femoral nerve compression caused by a hibernoma in the right thigh: a case report and literature review. BMC Surg. 2021;21(1):30. doi:10.1186/s12893-020-01040-y

5. Beidas KF, Sawan H, Alwatban F, AlHazzazi K, Beidas T. A case report of hibernoma in the thigh comprising the femoral neuromuscular bundle. Int J Surg Case Rep. 2021;89:106575. doi:10.1016/j.ijscr.2021.106575

6. Faenza M, Boffo R, Crisci E, Franzese G, Pagliuca F, D'Addato C. A large thigh hibernoma in a 23-years-old man: case report. Int J Surg Case Rep. 2024;123:110229. doi:10.1016/j.ijscr.2024.110229

7. Al Hmada Y, Schaefer IM, Fletcher CDM. Hibernoma mimicking atypical lipomatous tumor: 64 cases of a morphologically distinct subset. Am J Surg Pathol. 2018;42(7):951-7.

8. Gagnier JJ, Kienle G, Altman DG, Moher D, Sox H, Riley D; CARE Group. The CARE guidelines: consensus-based clinical case report guideline development. J Clin Epidemiol. 2014;67(1):46-51.

Copyright: © 2026 All rights reserved by Chaar O and other associated authors. This is an open access article distributed under the Creative Commons Attribution License, which permits unrestricted use, distribution, and reproduction in any medium, provided the original work is properly cited.