

Stump Appendicitis in a Pediatric Patient: Late Diagnosis of a Rare Entity. A Case Report and Brief Review of the Literature

Villamizar J^{1*}, Parada O¹, Clavijo L², Díaz A²

¹Erasmus Meoz University Hospital, Cúcuta, Colombia.

²University of Pamplona, Faculty of Health, Pamplona, Colombia.

*Corresponding Author: Joaquin Enrique Villamizar Zuñiga, Pediatric Surgeon, Erasmus Meoz University Hospital, Cúcuta, Colombia.

<https://doi.org/10.58624/SVOAPD.2026.05.006>

Received: February 20, 2026

Published: April 08, 2026

Citation: Villamizar J, Parada O, Clavijo L, Díaz A. Stump Appendicitis in a Pediatric Patient: Late Diagnosis of a Rare Entity. A Case Report and Brief Review of the Literature. SVOA Paediatrics 2026, 5:2, 42-46. doi: 10.58624/SVOAPD.2026.05.006

Abstract

Background: Stump appendicitis is a rare but potentially serious complication caused by inflammation of residual appendiceal tissue after appendectomy. It may occur days to decades following the initial surgery and is frequently associated with delayed diagnosis and increased risk of perforation, reported in up to 70% of cases. Awareness of this entity in pediatric populations remains limited.

Case Presentation: An 11-year-old male with a history of open appendectomy performed two years earlier presented with a five-day history of progressive right lower quadrant abdominal pain and fever (38°C). Physical examination revealed a positive McBurney sign. Laboratory findings showed leukocytosis (16,160 cells/mm³), neutrophilia (82%), and elevated C-reactive protein (134.43 mg/dL), with a modified Pediatric Appendicitis Score (PAS) of 7. Abdominal ultrasound demonstrated a non-compressible tubular structure in the right iliac fossa measuring 10 mm in diameter and 23 mm in length, consistent with stump appendicitis. A multiport laparoscopic completion appendectomy was performed, revealing a 4 cm phlegmonous, non-perforated appendiceal stump. Histopathology confirmed transmural polymorphonuclear inflammatory infiltration and mucosal ulceration.

Conclusion: Stump appendicitis should be considered in patients with prior appendectomy presenting with right lower quadrant pain, regardless of the time elapsed since surgery. Early clinical suspicion and appropriate imaging are essential to prevent complications.

Keywords: Appendicitis; Appendectomy; Child; Laparoscopy; Abdominal Pain.

Introduction

Stump appendicitis is the inflammation of the residual appendiceal tissue that occurs days to years after an appendectomy. This condition occurs after open or laparoscopic appendectomies where the remaining appendicular tissue is very long. It is one of the rare complications of late-diagnosed appendicitis. It should be suspected in any patient with a history of appendectomy who has pain in the right iliac fossa. The lack of knowledge of this entity can generate dilemmas to establish its diagnosis, thus delaying the surgical time, increasing its risk of perforation up to 40 to 70%. Ultrasound (US) and Computed tomography (CT) scans of the abdomen are helpful tools to confirm the diagnosis. The imaging findings reported are similar to those of acute appendicitis. [1-4]

We report a case of stump appendicitis in an 11-year-old male patient, with a history of open appendectomy 2 years ago in Venezuela. Who presented suggestive symptoms of acute appendicitis, with diagnostic confirmation by abdominal US. We emphasize the importance of diagnostic suspicion despite the time elapsed after the initial surgery. [5-8]

Case Presentation

An 11-year-old male patient with history of open appendectomy, performed 2 years ago for acute appendicitis in Venezuela, was admitted to the Pediatric Emergency Department with high intensity abdominal pain in crescendo in the right lower quadrant of 5 days of evolution and temperature of 38C, no other signs and symptoms. On physical examination, positive McBurney sign was found. He received analgesic management at home with Hyoscine Butyl Bromide for 2 days, without improvement.

Intrahospital paraclinics revealed:

- Leukocytosis (16,160 cells/mm³)
- Neutrophilia (82%)
- C-reactive protein (134.43 mg/dL).

With a total score on the modified Pediatric Appendicitis Score (PAS) scale (Table 1) of 7 points, suggesting a high risk of acute appendicitis.

The total abdominal US report describes a fixed tubular image in the right iliac fossa of 10mm in transverse diameter and 23 mm in length, highly suggestive of stump appendicitis (See Figure 1). He was referred to the paediatric surgery service, where a multiport laparoscopic appendectomy was performed by intraumbilical Hasson incision and 2 trocars of 5mm in hypogastrium and left iliac fossa, identifying a non-perforated phlegmonous appendicular stump of approximately 4cm in length (See Figure 2); The procedure was performed by releasing periappendicular adhesions from the appendix with ultrasonic scissors and the appendicular base is ligated with silk 2-0, Roeder's knot and the residual limb is extracted through the umbilical trocar. A sample was sent to pathology who reported microscopic findings: cecal appendix with preserved histological architecture, ulceration of the mucosa, polymorphonuclear inflammatory infiltrate that compromises the entire thickness of the mucosa and wall without periappendicular involvement (See Figures 3,4).

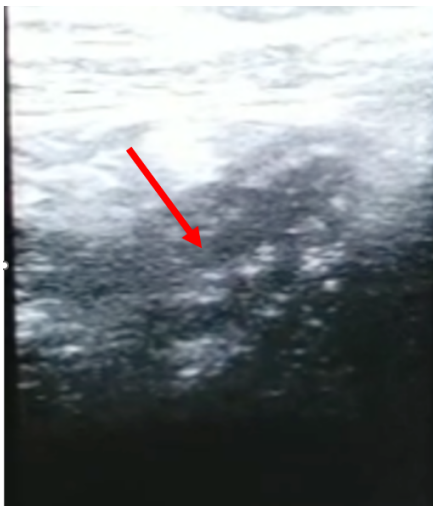


Figure 1. Abdominal ultrasound showing (red arrow) the appendicular stump with a diameter of 10mm and a length of 23 mm.

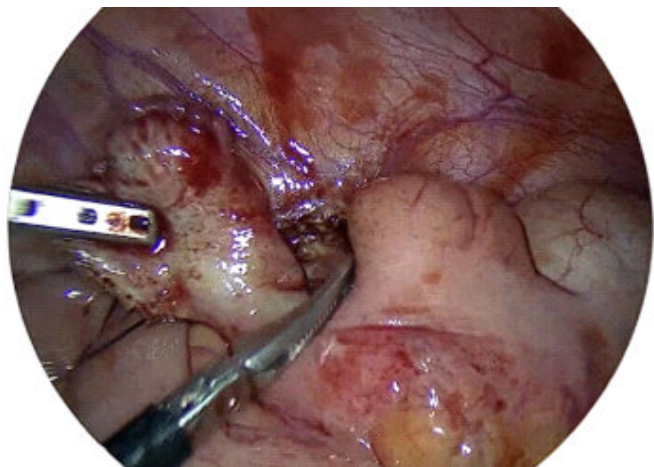


Figure 2. Phlegmonous non-perforated appendicular stump.

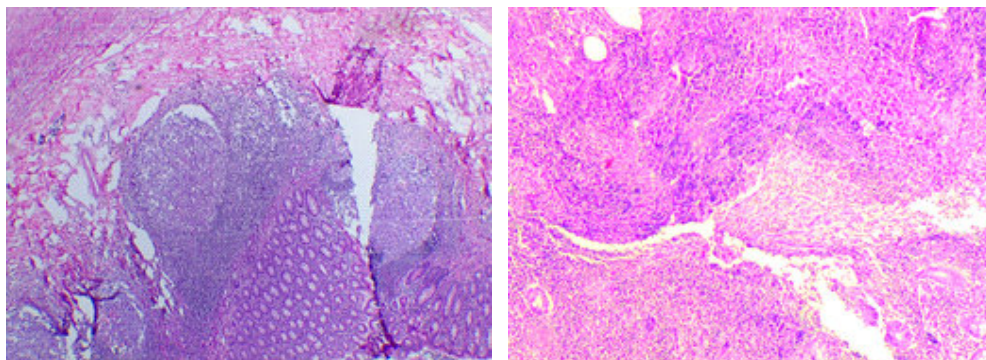
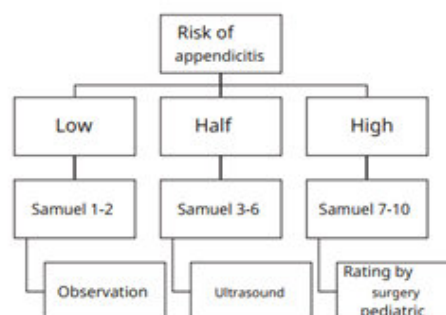


Figure 3-4. 10x histology of appendicular stump showing mucosal ulceration, polymorphonuclear inflammatory infiltrate involving the entire mucosal thickness and wall.

Table 1. Samuel's modified scale for the diagnosis of acute appendicitis in pediatrics.

| Table 1 - Samuel's modified scale for diagnosis of acute appendicitis in pediatrics | |
|---|-------|
| Parameter | Score |
| Pain migration | 1 |
| Pain in right iliac fossa with movement | 2 |
| Pain in right iliac fossa on palpation | 2 |
| Anorexy | 1 |
| Nausea/vomiting | 1 |
| Fever | 1 |
| Leukocytosis with neutrophilia | 1 |
| C-reactive protein positive | 1 |



Source: Rodriguez S, Becerra M, & Rueda S. (2016). Validation of an electronic clinical history program that guides the study of acute appendicitis in pediatrics. *Pediatrics*, 49(1), 8–16. doi:10.1016/j.rcpe.2016.02.003

Discussion

Stump appendicitis is the development of inflammation of the remaining portion of the appendix after an appendectomy [1]. Its occurrence rate was reported in a systematic analysis with appendicular lengths ranging from 0.5 cm to 6.5 cm (mean 2.14 cm) of residual appendix after an initial appendectomy [2,3]. It can occur from days to years after surgery, post-surgical presentation range between 1 day and 58 years is reported in the literature and the symptomatology is similar to those of appendicitis [1,4].

However, its diagnosis is differential and should be suspected in patients with pain in the right lower quadrant with a history of previous appendicular resection [1]. Lack of knowledge of this pathology delays surgical intervention, increasing the risk of complications such as perforation by 40 to 70% and peritonitis [4,5].

There is no specific cause for the development of stump appendicitis and despite postulated by researchers in the 1990s attempting to link laparoscopic appendectomy with stump appendicitis, to date there is no proven causal relationship based on available scientific evidence [5,6] and may occur after an open or laparoscopic approach [7]. It is suggested as associated factors the late diagnosis of acute appendicitis, complicated surgeries, a difficult dissection of the appendix, the retrocecal, high or subserous anatomical position are suggested as associated factors, since technically it conditions a difficult identification of the base of the cecum's base due to the inflammatory process, causing a wide length of the appendicular stump after appendectomy [2,8], and it can occur with or without a discernible accumulation of appendicolite or pericecal fluid.

CT and US of the abdomen are equally useful for the diagnosis of stump appendicitis, and imaging findings may be similar to those seen in acute appendicitis [2]; Through US, the entire appendicular extension is identified, which goes from the tip to the base that goes into the cecum, paying special attention to the longitudinal diameter greater than 6 mm, and this finding is highly suggestive of stump appendicitis [9]. However, due to the uncommon occurrence of this pathology, a cross-sectional CT scan of the abdomen with contrast is recommended, as this allows a more detailed visualization of the distension of the appendicular stump, pericecal inflammatory changes, abscess formation, presence of fluid in the right paracolic space, thickening of the wall of the cecum or an ileocecal mass [10,11]. In children, this CT scan should be taken with special protection to decrease irradiation. In situations of diagnostic uncertainty with persistent abdominal symptoms, when other entities have been ruled out through an exhaustive imaging analysis, diagnostic laparoscopy can be useful and, if the diagnosis of stump appendicitis is confirmed, allows complete stump appendectomy to be performed safely [12].

Stump appendicitis can complicate both open and laparoscopic appendectomy [13]. Treatment for stump appendicitis is complete appendectomy (CA), either with or without stump inversion [2]. This intervention can be performed as an open surgery or through a laparoscopic approach, and the choice depends on several factors, including the patient's clinical condition, the experience or resources available in the local hospital setting [2]. Laparoscopic appendectomy is recommended over open surgery because of its ability to provide a superior viewing angle, resulting in a more accurate differential diagnosis. Despite this, there is no established consensus on the surgical approach [14].

Conclusion

Stump appendicitis is an uncommon but clinically significant complication that should be included in the differential diagnosis of right lower quadrant pain in patients with previous appendectomy. Prompt recognition and appropriate imaging are critical to prevent complications. Laparoscopic completion appendectomy remains a safe and effective treatment modality.

Conflict of Interest

The authors declare no conflicts of interest.

Funding

No external funding was received for this study.

References

1. Liang M, Lo H, Marks J: Stump appendicitis: a comprehensive review of literature. *Am Surg.*, 2006; 72(2): 162–166.
2. Salati S.A.: Stump appendicitis – a systematic analysis; *Pol Przegl Chir* 2021; 93: (1–7); DOI: 10.5604/01.3001.0015.4553
3. Ismail I, Lusco D, Jannaci M, Navarra G, Grassi A, Prompt recognition of stump appendicitis is important to avoid serious complications: a case report. *Cases Journal*, 2009; 2: 7415. doi: 10.4076/1757-1626-2-7415
4. Geraci G, Lena A, D'Orazio B, Cudia, B, Rizzuto S, & Modica G. (2019). A rare clinical entity: stump appendicitis. Case report and complete review of literature. *La Clinica terapeutica*, 170 6, e409-e417
5. Kanon A, Al Samaraee A, Nice C, Bhattacharya V. (2012). Stump appendicitis: A review. *International Journal of Surgery*, 10(9), 425–428. doi:10.1016/j.ijso.2012.07.007

6. Wright T, Diaco J. Recurrent appendicitis after laparoscopic appendectomy. *Int Surg*, 1994; 79(3): 251–252.
7. Manatakis D, Aheimastos V, Antonopoulou M, Agalianos C, Tsiaoussis J, & Xynos E. (2019). Unfinished Business: A Systematic Review of Stump Appendicitis. *World Journal of Surgery*, 43, 2756 - 2761. <https://doi.org/10.1007/s00268-019-05101-z>.
8. Sharma A, Khullar R, Soni V, Baijal M, Chowbey P, Kumar A. (2013). Stump appendicitis: A rare clinical entity. *Journal of Minimal Access Surgery*, 9(4), 173. doi:10.4103/0972-9941.118835
9. Monsomboon A, Nelson B, Andrus P, Tsung J. (2019). Point-of-care ultrasound diagnosis of stump appendicitis in the emergency department. *The Ultrasound Journal*, 11(1). doi:10.1186/s13089-019-0128-5
10. Awe J, Soliman A, Gourdie R: Stump appendicitis: An uncompleted surgery, a rare but important entity with potential problems. *Case Rep Surg*, 2013; ID972596; p4
11. Artul S, Daud M, Abboud N, Assaf V: Stump appendicitis: a challenging diagnosis. *Case Rep*, 2014; 2014: bcr2014206775.
12. Botianu P, Botianu A, Boeriu C: Laparoscopic management of stump appendicitis after open appendectomy. *J Surg*, 2016; 12(1): 37–38.}
13. Al-Dabbagh A, Thomas N, Haboubi N: Stump appendicitis. A diagnostic dilemma. *Tech Coloproctol*, 2009; 13: 73–74
14. Roberts K, Starker L, Duffy A, Bell R, Bokhari J: Stump appendicitis: a surgeon's dilemma. *JLS*, 2011; 15(3): 373–378

Copyright: © 2026 All rights reserved by Villamizar J and other associated authors. This is an open access article distributed under the Creative Commons Attribution License, which permits unrestricted use, distribution, and reproduction in any medium, provided the original work is properly cited.